Review

trd Tuberculosis & Respiratory Diseases

Advanced Bronchoscopic Diagnostic Techniques in Lung Cancer

https://doi.org/10.4046/trd.2023.0147
ISSN: 1738-3536(Print)/2005-6184(Online)
Tuberc Respir Dis, Published online Feb. 28, 2024

Dongil Park, M.D., Ph.D.
Division of Pulmonology and Critical Care Medicine, Department of Internal Medicine, Chungnam National University College of Medicine, Daejeon, Republic of Korea

Address for correspondence
Dongil Park, M.D., Ph.D.
Division of Pulmonology and Critical Care Medicine, Department of Internal Medicine, Chungnam National University Hospital, 282 Munhwa-ro, Jung-gu, Daejeon 35015, Republic of Korea
E-mail rahm3s@gmail.com
Received Oct. 6, 2023
Revised Dec. 28, 2023
Accepted Feb. 22, 2024
Published online Feb. 28, 2024

Abstract

The increasing incidence of incidental pulmonary nodules necessitates effective biopsy techniques for accurate diagnosis and treatment planning. This paper reviews the widely used advanced bronchoscopic techniques, such as radial endobronchial ultrasound-guided transbronchial lung biopsy, electromagnetic navigation bronchoscopy, and the cutting-edge robotic-assisted bronchoscopy. In addition, the cryobiopsy technique, which can enhance diagnostic yield by combination with conventional biopsy tools, is described for application to peripheral pulmonary lesions and mediastinal lesions, respectively.

Keywords: Bronchoscopy; Biopsy; Lung Cancer; Endobronchial Ultrasound; Electromagnetic Navigation Bronchoscopy; Robotic-Assisted Bronchoscopy; Cryobiopsy

Introduction

Lung cancer is the leading cause of cancer-related mortality worldwide[1]. As a result of the National Lung Screening Trial (NLST), screening using low-dose computed tomography (CT) in high-risk groups aged 55 to 74 with a 30 pack-year or more smoking history reduced the mortality rate from lung cancer by 20%[2]. In addition, the United States Preventive Task Force (USPSTF) recommends annual screening for lung cancer with low-dose CT in adults aged 50 to 80 years who have a 20 pack-year smoking history and currently smoke or have quit within the past 15 years, according to the results of the Nelson Trial[3,4]. Accordingly, incidental pulmonary nodules are increasing[5,6].

The National Comprehensive Cancer Network (NCCN) guidelines suggest that biopsy should be considered if an incidentally discovered pulmonary nodule is larger than 8 mm and the patient belongs to a high-risk group for lung cancer[7]. Pathological examination through biopsy can also determine whether a patient has primary lung cancer or metastatic cancer, and classify the histologic subtype of lung cancer. A sufficient amount of tissue is required to predict the therapeutic response to driver mutations or immune checkpoint inhibitors[7].

Transbronchial lung biopsy with radial endobronchial ultrasound (rEBUS-TBLB) and CT-guided transthoracic needle biopsy (CT-TTNB) are two commonly used methods to investigate peripheral lung nodules. According to a meta-analysis of randomized controlled trials, CT-TTNB had a higher diagnostic yield than rEBUS-TBLB (83.45% vs. 68.82%; risk difference, −0.15; 95% confidence interval [CI], −0.24 to −0.05) especially for lesion size 1 to 2 cm (83% vs. 50%; risk difference, −0.33; 95% CI, −0.51 to −0.14). However, rEBUS-TBLB was found to have a significantly better safety profile with lower risks of pneumothorax (2.87% vs. 21.43%;

odds ratio [OR], 0.12; 95% CI, 0.05 to 0.32) and combined outcomes of hospital admission, hemorrhage, and pneumothorax (8.62% vs. 31.81%; OR, 0.21; 95% CI, 0.11 to 0.40)[8].

Recently, new techniques, such as robotic-assisted bronchoscopy (RAB), have been introduced to complement the diagnostic yield of rEBUS-TBLB[9]. Additionally, studies have been published on improving diagnostic yield using cryobiopsy, along with conventional biopsy devices[10-12]. In this review, we describe both widely used, and newly introduced, advanced bronchoscopy techniques.

Radial Endobronchial Ultrasound-Guided Transbronchial Lung Biopsy

The rEBUS-TBLB uses a miniature ultrasound probe (rEBUS probe) that emits ultrasound waves that are reflected by the tissue, creating a 360° real-time image of the airway and the surrounding lung tissue. This allows the physician to identify the location of the lesion, and guide the biopsy devices to the target lesion for biopsy. The rEBUS probe is inserted through the working channel of a flexible bronchoscope or catheter (guide sheath [GS]). This enables the clinician to determine the lesion's exact location and size[13,14].

In a recent systematic review and meta-analysis that included 51 studies with a total of 7,601 subjects, the pooled sensitivity of rEBUS-TBLB was 0.72 (95% CI, 0.70 to 0.75), and the area under the receiver operating characteristic (ROC) curve was 0.96 (95% CI, 0.94 to 0.97), while the pneumothorax incidence rate was only 0.7% (95% CI, 0.3 to 1.1)[15].

1. With GS versus without GS

A GS is a thin tube that is used in conjunction with a rEBUS probe during bronchoscopy biopsy. The GS is inserted through the working channel of a flexible bronchoscope, and helps to improve diagnostic yield and safety profile by allowing for more accurate placement of the biopsy forceps or needle. In addition, one study found that using a GS as an extended working channel (EWC) helps minimize bleeding risk during TBLB in high-risk patients. The researchers hypothesized that the EWC produces a tamponade effect in the close vicinity of the biopsy site, both reducing bleeding risk, and restricting bleeding to a smaller segment[16].

One multicenter retrospective cohort study compared the diagnostic yield, complication rate, and procedure time of rEBUS-TBLB with and without a GS for malignant peripheral pulmonary lesions (PPLs). Adding a GS to rEBUS-TBLB did not improve the diagnostic yield for malignant PPLs (79% vs. 78%; p=0.649). GS guidance was seemingly associated with a lower number of complications (7.2% vs. 5.8% for bleeding; 1.9% vs. 0.6% for pneumothorax), but contributed significantly to a longer procedure time (29 minutes vs. 24 minutes, p<0.001)[17].

However, according to a recent multicenter study randomized trial, the use of a GS during rEBUS-TBLB enhances the diagnostic yield for small PPLs (<30 mm in diameter). The study found that the diagnostic yield of histological specimens from the group using a GS was significantly higher than that from the group without a GS (55.3% vs. 46.6%, p=0.033)[18].

2. rEBUS-GS-TBLB combined with the conventional forceps TBLB

The rEBUS-GS-TBLB improves the diagnostic yield from PPLs[18]. However, one disadvantage of using small 1.5 mm forceps through a GS during rEBUS-GS-TBLB is that the small specimens obtained may impede diagnosis. In contrast, the conventional TBLB using larger 1.8 to 1.9 mm forceps may provide larger specimens that are more suitable for diagnosis and molecular analysis[19].

Kunimasa et al.[20] evaluated the diagnostic utility of performing additional conventional TBLB with standard forceps after rEBUS-GS-TBLB for the diagnosis of PPLs. The results showed that of the 88 eligible patients, 57 (65%) were successfully diagnosed by rEBUS-GS-TBLB. In the 31 patients not diagnosed by rEBUS-GS-TBLB, 15 (48%) were successfully diagnosed by additional conventional TBLB. The researchers concluded that additional conventional TBLB could be useful in cases where the distance between the rEBUS probe and the lesion is less than 2.55 mm[20].

Park et al.[19] investigated the diagnostic significance of performing additional conventional TBLB with standard forceps after rEBUS-GS-TBLB. The study retrospectively reviewed data from 55 patients who underwent conventional TBLB after rEBUS-GS-TBLB for the diagnosis of PPLs. The results showed that rEBUS-GS-TBLB was diagnostic in 30 (54.5%) patients, and subsequent conventional TBLB yielded additional diagnostic information in eight (14.5%) patients[19].

3. Thin bronchoscope versus ultrathin bronchoscope

An ultrathin bronchoscope (UTB) is a type of bronchoscope that is smaller in diameter than a traditional thin bronchoscope (TB). It has a 2.8 to 3.2 mm diameter and a 1.2 to 1.7 mm working channel. This smaller size allows the UTB to access more peripheral areas of the

lung, which can be useful for diagnosing small PPLs[21].

Oki et al.[22] showed that in the diagnosis of PPLs, multimodal bronchoscopy using a UTB was superior to that using a TB. They conducted a randomized trial to compare multimodal bronchoscopy using a UTB and a TB with multiple sampling methods for the diagnosis of PPLs. The overall diagnostic yield was significantly higher in the UTB group than in the TB group (70.1% vs. 58.7%, p=0.27), and the procedure duration was significantly shorter in the UTB group (median, 24.8 minutes vs. 26.8 minutes, p=0.008). The complication rates were 2.8% and 4.5%, respectively (p=0.574).

In real practice, a UTB is frequently used subsequent to an unsuccessful access attempt using a rEBUS-guided approach. A multicenter prospective study found that the use of UTB in addition to TB improved the diagnostic yield for PPLs. In this study, 87 (87/342, total n=342) PPLs without 'within' orientation on the rEBUS image were subsequently accessed using UTB. The diagnostic yield increased from 12.6% to 46.0% (11/87 to 40/87) by the addition of UTB[22].

Electromagnetic Navigation Bronchoscopy

Electromagnetic navigation bronchoscopy (ENB) is a medical procedure that utilizes electromagnetic technology to localize and guide endoscopic tools or catheters. The magnetic field and generator create a low-intensity electromagnetic field around the patient's chest, which allows the location sensor at the tip of the guide catheter to be tracked in real time. The computer software uses the sensor data to display the position of the catheter on a three-dimensional (3D) bronchial map, which helps the physician navigate to the target lesion[23].

In 2004, the Medtronic superDimension/Bronchus system, also known as the inReach system (superDimension Ltd., Herzliya, Israel), was approved by the Food and Drug Administration (FDA). Using electromagnetic guidance to manage peripheral lung lesions, this system is a minimally invasive image-guidance localization and navigation system.

The NAVIGATE study, a large, multicenter cohort study including 1,215 consecutive subjects from 29 sites, showed a diagnostic yield of 73% at 1-year follow-up results. This study diagnostic yield was comparable to other studies, even though it included only 48.5% (60% to 70% in other studies) of subjects with a positive computed tomography bronchus sign (CTBS), which is known as a significant favorable factor[24-27]. In other studies, when CTBS is negative, the diagnostic yield is only 31% to 49.6%, but in the NAVIGATE study, it was reported to be 67.1%[25,28].

1. What brought about this difference?

In the NAVIGATE study, three or more biopsy tools were used in 72.7% of cases, and the diagnostic yield was significantly higher, compared to when less than three tools were used (OR, 1.44; 95% CI, 1.01 to 2.04; p=0.04)[27]. Although this was not replicated in the 24-month results, it is possible that the use of new instruments capable of penetrating the normal bronchial barrier between the bronchi and the target lesion improved accessibility in CTBS-negative lesions (Figure 1)[29].

A recent systematic review and meta-analysis of the sensitivity and safety of ENB reported a pooled sensitivity of 77% (95% CI, 72% to 82%; I^2=80.6%) and a

Figure 1. Penetrating biopsy tools used in NAVIGATE study (https://www.medtronic.com/covidien/en-us/products/interventional-lung-solutions/pulmonary-and-biopsy-tools.html).

specificity of 100% (95% CI, 99% to 100%; I^2=0%) for malignancy. ENB achieved a sufficient sample for ancillary tests in 90.9% (95% CI, 84.8% to 96.9%; I^2=80.7%). The risk of pneumothorax was 2.0% (95% CI, 1.0% to 3.0%; I^2=45.2%)[30].

Therefore, to date, ENB has shown comparable results to rEBUS-TBLB in terms of diagnostic performance and safety[15].

Robotic-Assisted Bronchoscopy

RAB is a procedure that uses a robotic arm to guide a flexible tube with a camera and biopsy tools into the lungs. RAB systems were designed to reach the peripheral lung airways, similar to the traditional electromagnetic navigation system, but with better stability and steerability during the biopsy. There are currently two RAB systems available: the Monarch platform (Auris Health Inc., Redwood City, CA, USA), and the ion endoluminal system (Intuitive Surgical, Sunnyvale, CA, USA). While the two systems are similar in planning the path to the target lesion using a 3D airway map reconstructed from pre-procedure thin-section chest CT images, the navigation principles are totally different.

1. Monarch robotic platform

The Monarch platform basically uses the principle of ENB to navigate to the target lesion. The Auris Bronchoscope is made up of two parts: an inner scope of 4.4 mm diameter, and an outer sheath of 6.0 mm diameter. The bronchoscope is equipped with a camera that provides the visual inspection, as well as an integrated light source. Additionally, the bronchoscope has a working channel of 2.1 mm inner diameter, which allows for the insertion of biopsy tools and rEBUS probe (Figure 2). The outer sheath can be inserted into the lobar or segmental bronchus, and peripheral lung lesions are then approached using the inner scope.

Chaddha et al.[31] retrospectively reviewed data on consecutive cases in which robot-assisted bronchoscopy was used to sample lung lesions at four centers in the United States (academic and community) from June 15th, 2018 to December 15th, 2018. The study found that navigation was successful in 88.6% of cases, while tissue samples were successfully obtained in 98.8% of cases. The diagnostic yield estimates ranged 69.1% to 77%, depending on whether the cases of biopsy-proven inflammation without any follow-up information were considered non-diagnostic or diagnostic. Pneumothorax and significant bleeding occurred in 3.6% and 2.4% cases, respectively[31].

The Robotic Bronchoscopy for Peripheral Pulmonary Lesions: A Multicenter Pilot and Feasibility Study (BENEFIT) is the first prospective, multicenter study that evaluated the use of a robotic bronchoscopic system in patients with PPLs ranging 1 to 5 cm in size. The study aimed to evaluate the success of lesion localization using rEBUS, and the incidence of procedure-related adverse events. The results showed that lesion localization was successful in 96.2% of cases, and the rate of adverse events was comparable to that of conventional bronchoscopic procedures. Post-procedural pneumothorax was found in 3.7% (2/54) of cases, with 1.9% (1/54) of cases requiring tube thoracostomy. The diagnostic yield was 74.1% (40/54).

2. Ion endoluminal system

The ion endoluminal system navigates to PPLs in a completely different way than other RAB platforms. This is termed shape-sensing technology, and uses

Figure 2. (A) Monarch Platform. (B) Screen during navigation (https://www.jnjmedtech.com/en-US/product-family/monarch).

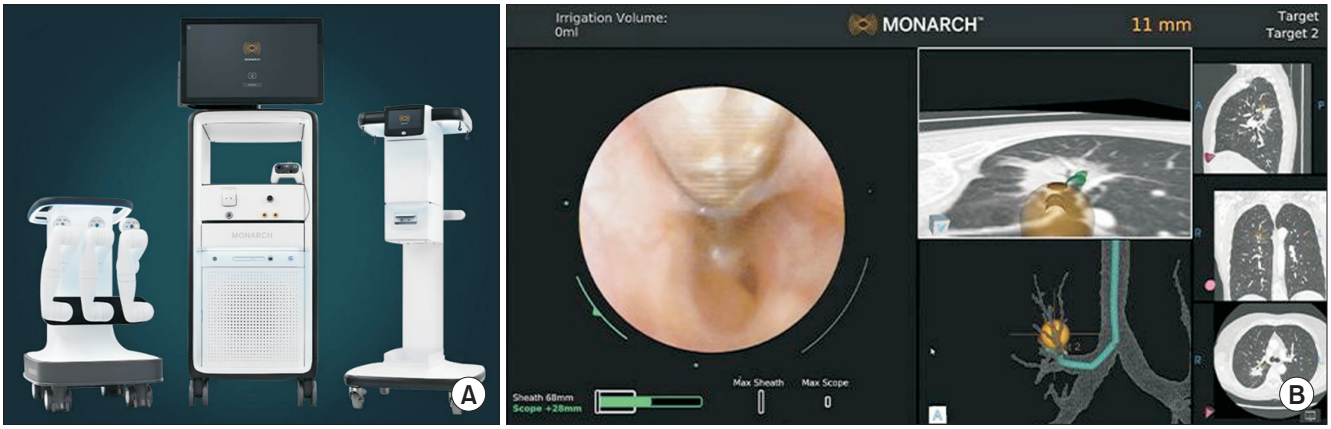

sensors to detect and measure the shape or deformation of an object. The ion endoluminal system uses this technology to provide real-time location information for the dedicated scope as it navigates through the small and complex airways of the lungs. Unlike the Monarch platform, the ion endoluminal system uses a single ultrathin scope of 3.5 mm outer diameter and 2.0 mm working channel (Figure 3).

Recently published retrospective studies using the shape-sensing robotic-assisted bronchoscopy (ssRAB) have reported remarkable results. Kalchiem-Dekel et al.[32] conducted a retrospective analysis of data from consecutive cases at a cancer center in the United States from October 2019 to July 2020. During the procedures, 159 pulmonary lesions were targeted. The median size of the lesions was 18 mm, with 59.1% located in the upper lobe, and 66.7% beyond a sixth-generation airway. The success rate of navigation was 98.7%, while the diagnostic yield was 81.7%. The overall complication rate was 3.0%, and the pneumothorax rate was 1.5%[32].

Styrvoky et al.[33] reported that when ssRAB was combined with rEBUS and cone beam CT, the diagnostic accuracy reached 91.4%. Two hundred ssRAB procedures were performed to sample 209 nodules in 198 patients. The median size of the lesions was 19 mm, with 47.8% located in the periphery. Pneumothorax was the sole complication, occurring in 1% (two out of 200) of the procedures, with half of those cases necessitating the insertion of a chest tube[33].

Yu Lee-Mateus et al.[9] retrospectively analyzed the diagnostic performance of ssRAB and computed tomography-guided transthoracic biopsy (CTTB). The study included a total of 225 participants, with 113 assigned to the ssRAB group, and 112 to the CTTB group. The overall diagnostic yield was 87.6% for ssRAB, and 88.4% for CTTB. In terms of malignancy, ssRAB demonstrated a sensitivity of 82.1% and a specificity of 100%, while CTTB exhibited a sensitivity of 88.5% and a specificity of 100%. Complication rate was significantly higher for CTTB compared to RAB (17% vs. 4.4%, p=0.002). Four patients in the RAB group and 18 in the CTTB group experienced a pneumothorax that necessitated hospital admission for monitoring or the insertion of a chest tube[9].

A Prospective Evaluation of the Clinical Utility for the Ion Endoluminal System (PRECIsE) study is a prospective, multicenter, single-arm, clinical study that enrolled subjects ≥18 years old with solid or subsolid pulmonary nodules of greater than 1 cm but less than 3.5 cm diameter. The aim of the study was to evaluate the clinical utility and performance of ssRAB[34]. The study reported preliminary data from 69 subjects who were enrolled across six medical centers, beginning in March 2019. Mean nodule diameter was 17.0±5.5 mm, and the incidence of CTBS was 25%. The diagnostic yield was 83% (57/69). The study reported similar diagnostic yield for both smaller and larger nodules. Nodules of 1 to 2 cm diameter showed a diagnostic yield of 82% (40/49), while nodules of 2 to 3 cm diameter showed a diagnostic yield of 85% (17/20). There was no pneumothorax complication requiring chest tube insertion[35].

Transbronchial Lung Cryobiopsy

The development of cryobiopsy technology was inspired by the Joule-Thomson principle, where rapid freezing occurs with the sudden expansion of certain

Figure 3. (A) Ion endoluminal system. (B) Shape-sensing catheter technology (https://www.intuitive.com/en-us).



gases as they move from a high-pressure to a low-pressure environment[36]. Transbronchial lung cryobiopsy (TBLC) has been widely accepted as a biopsy method for interstitial lung diseases[37]. This technique utilizes a freezing probe to collect lung tissue samples that are superior in size and quality, compared to those obtained through conventional TBLB[38]. Cryobiopsy can be used in combination with ENB or RAB, as well as conventional biopsy modalities, to improve diagnostic yield[39,40].

Recently, TBLC has been widely used in the diagnosis of PPLs. In particular, with the development of a 1.1 mm cryoprobe, it has become possible to perform cryobiopsy through a GS following conventional biopsies, such as forceps, aspiration needle, and brushing, when performing rEBUS-GS-TBLB[10-12].

It has been reported that when cryobiopsy is used in combination with the conventional biopsy methods, diagnostic yield increases. In the case of 'adjacent to' on rEBUS, relatively higher benefit can be obtained than in the case of 'within.' Several retrospective studies have reported that when cryobiopsy is performed following conventional biopsy in the 'adjacent to' lesions, an additional diagnostic yield of 14.5% to 29.9% can be obtained[10-12]. In addition, Matsumoto et al.[11] reported that lesions with a negative bronchus sign had a relatively high additional diagnostic yield, compared to lesions with a positive bronchus sign (15.4% vs. 6.3%, p=0.011).

When cryobiopsy is performed in the 'adjacent to' orientation, a high additional diagnostic yield can be obtained, because normal anatomical structures (e.g., bronchial mucosa) are removed together when obtaining the cryobiopsy specimen. Therefore, as cryobiopsy is repeatedly performed, the location where the tissue is obtained gradually moves to the center of the lesion (Figure 4)[12].

In PPLs, cryobiopsy increases the risk of bleeding, but no deaths have been reported; it is known to be relatively safe to perform by an experienced operator, even in high-bleeding-risk patients[41,42].

Figure 4. A case in which a specimen containing adenocarcinoma was obtained through three crybiopsies (H&E stain, ×5). (A) The arrow indicates bronchial mucosa, and the dotted arrow indicates cartilage—'adjacent to' on radial endobronchial ultrasound (rEBUS). (B) Atypical cells are observed in the dotted oval—'adjacent to' on rEBUS. (C) Adenocarcinoma observed in dotted circle—'within' on rEBUS.

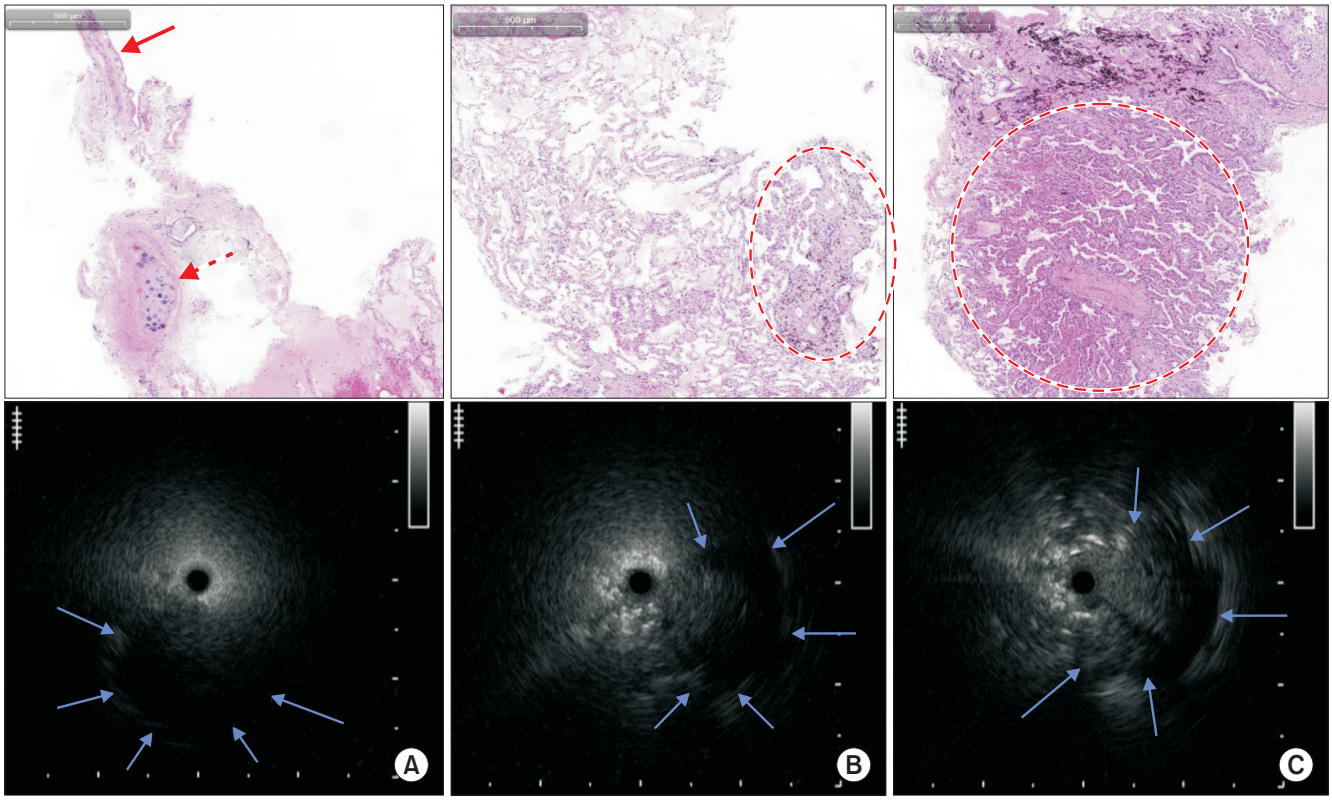

Transbronchial Mediastinal Cryobiopsy

Endobronchial ultrasound-guided transbronchial needle aspiration (EBUS-TBNA) plays a crucial role in the staging of lung cancer, particularly in determining the extent of mediastinal lymph node involvement. The diagnostic performance of EBUS-TBNA to identify malignancy in lymph nodes had a sensitivity of 92.3%, a specificity of 100%, and a negative predictive value of 96.3%[43].

The EBUS-TBNA can also be used for pathological diagnosis in central lesions and mediastinal lesions. However, the diagnostic yield of EBUS-TBNA in certain types of mediastinal lesions can be limited, due to the inability to obtain sufficient intact tissue samples. In diagnosing mediastinal tuberculosis lymphadenitis, the sensitivity and specificity were 72.4% and 100.0% respectively. For diagnosing sarcoidosis, the sensitivity and specificity were 71.4% and 100.0% respectively[44].

Transbronchial mediastinal cryobiopsy is a biopsy method that has been introduced in recent years, and is currently being performed in several institutions. It is performed by inserting a cryoprobe into the lesion combined with EBUS-TBNA. Typically, a 1.1 mm cryoprobe is used. This can provide larger and better-quality samples than EBUS-TBNA, which might improve the diagnostic yield for certain conditions, such as uncommon tumors and benign disorders (Figure 5)[45,46].

Fan et al.[45] carried out an open-label, randomized trial across three medical facilities in Europe and Asia. The study included patients who were 15 years or older, and had at least one mediastinal lesion measuring 1 cm or more on the short axis. Participants were randomly assigned (1:1) to the combined use of EBUS-TBNA and transbronchial mediastinal cryobiopsy (combined group, n=136) or EBUS-TBNA alone (control group, n=135). When mediastinal cryobiopsy was added to the conventional EBUS-TBNA, the overall diagnostic yield increased from 81% to 93% (p=0.0039). When cryobiopsy was added in benign diseases, the diagnostic yield was significantly higher than the EBUS-TBNA alone group (34% vs. 24%, p=0.0009). However, there was no significant difference in diagnostic yield between the two groups in lung cancer and uncommon tumors[45]. Grade 3 or higher bleeding occurred in two patients (1%) and three patients (2%) in the EBUS-TBNA alone group and combined group, respectively (p=1.00), while pneumothorax occurred in four patients (3%) and two patients (1%), respectively (p=0.67).

Genomic testing for lung cancer and programmed death-ligand 1 (PD-L1) immunohistochemistry assay were applicable in nearly all (37 out of 38, 97%) of the non-small-cell lung cancer samples obtained through the combined method, while they were only feasible in 30 (79%) out of 38 samples from the EBUS-TBNA alone method (relative risk, 1.23; 95% CI, 1.04 to 1.47; p=0.033).

Therefore, to date, there is little evidence of the need for mediastinal cryobiopsy in terms of diagnostic yield for lung cancer, but when genomic testing and PD-L1

Figure 5. Size comparison of lymph node between specimens obtained by endobronchial ultrasound-guided transbronchial needle aspiration (EBUS-TBNA) and cryobiopsy (A) 21G EBUS-TBNA—the diameter of the area containing adenocarcinoma is 270 μm. (B) A 1.1 mm cryoprobe—1,950 μm (H&E stain, ×2).

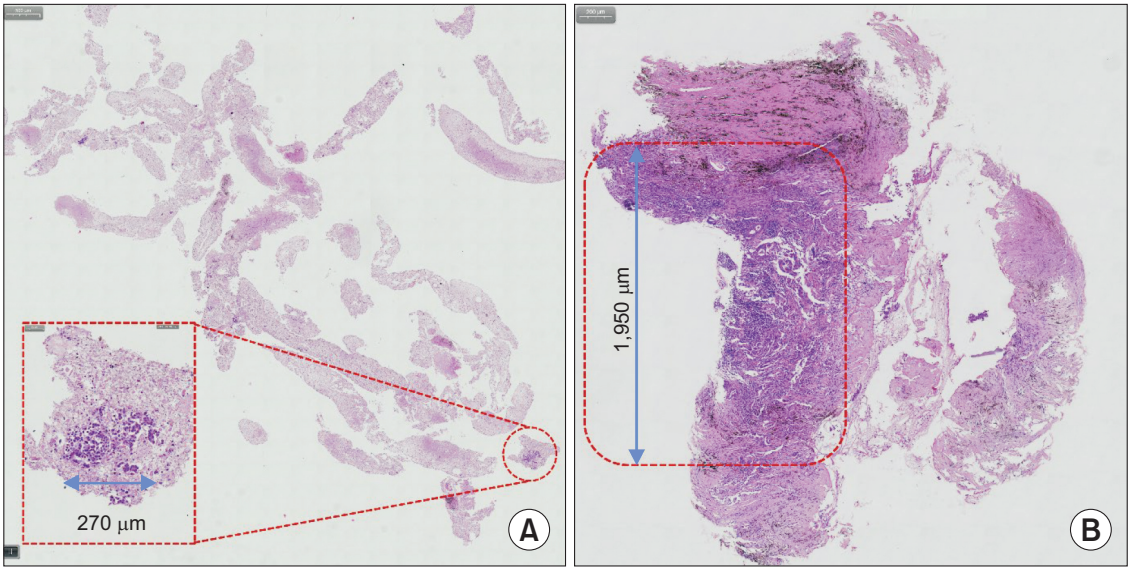

immunohistochemistry assay are necessary, it can be considered.

EBUS-Guided Intranodal Forceps Biopsy & Flexible 19 G Needle for EBUS-TBNA

A meta-analysis indicates that the addition of forceps to conventional EBUS-TBNA enhances diagnostic accuracy in the tissue diagnosis of intrathoracic adenopathy. This study demonstrates a significant increase in diagnostic yield with the combined method, achieving 92% (428 out of 467 cases), compared to a 67% yield (312 out of 467 cases) when utilizing EBUS-TBNA alone. Notably, in specific pathologies, such as lymphoma and sarcoidosis, the combined approach substantially elevates diagnostic yield: 86% for lymphoma vs. 30% for EBUS-TBNA alone, and 93% for sarcoidosis, in contrast to 58% with the solitary EBUS-TBNA method[47].

Studies using 19-gauge TBNA needles were conducted to overcome the limitations of standard 21- and 22-gauge EBUS-TBNA needles, which have a small amount of core and a crushed structure. These studies revealed that while the use of a 19-gauge needle did not enhance the diagnostic yield, it facilitated the acquisition of larger tissue samples, proving more beneficial for comprehensive histopathological evaluation and molecular testing without an increase in complications[48,49]. Although the 19-gauge needle may have potential benefits in situations necessitating the assessment of cellular architecture, such as in lymphoma subtyping or in the presence of necrotic tissues, definitive evidence supporting its superiority remains inconclusive to date. Therefore, the choice of needle gauge should be contingent upon individual patient needs and the specific requirements of the diagnostic evaluation.

Conclusion

With the development of various advanced bronchoscopic techniques, the minimally invasive non-surgical biopsy methods have become a trend in the diagnosis and staging of lung cancer. These techniques can be used alone, or in combination. When combined with conventional biopsy tools, cryobiopsy increases diagnostic yield, and can be used together during rEBUS-GS-TBLB, ENB, RAB, and EBUS-TBNA procedures.

Conflicts of Interest

No potential conflict of interest relevant to this article was reported.

Acknowledgments

This work was supported by the National Research Foundation of Korea (NRF) grant, funded by the Korean Government (MSIT) (No. 2022R1A2C2010148).

Funding

No funding to declare.

References

1. National Institutes of Health, National Cancer Institute. Cancer stat facts: lung and bronchus cancer [Internet]. Bethesda: NIH; 2023 [cited 2024 Mar 25]. Available from: https://seer.cancer.gov/statfacts/html/lungb.html.
2. National Lung Screening Trial Research Team; Aberle DR, Adams AM, Berg CD, Black WC, Clapp JD, et al. Reduced lung-cancer mortality with low-dose computed tomographic screening. N Engl J Med 2011;365:395-409.
3. de Koning HJ, van der Aalst CM, de Jong PA, Scholten ET, Nackaerts K, Heuvelmans MA, et al. Reduced lung-cancer mortality with volume CT screening in a randomized trial. N Engl J Med 2020;382:503-13.
4. US Preventive Services Task Force; Krist AH, Davidson KW, Mangione CM, Barry MJ, Cabana M, et al. Screening for lung cancer: US Preventive Services Task Force Recommendation Statement. JAMA 2021;325:962-70.
5. Okereke IC, Nishi S, Zhou J, Goodwin JS. Trends in lung cancer screening in the United States, 2016-2017. J Thorac Dis 2019;11:873-81.
6. Schmid-Bindert G, Vogel-Claussen J, Gutz S, Fink J, Hoffmann H, Eichhorn ME, et al. Incidental pulmonary nodules: what do we know in 2022. Respiration 2022;101:1024-34.
7. National Comprehensive Cancer Network. Non-small cell lung cancer (version 3.2023) [Internet]. Plymouth Meeting: NCCN; 2023 [cited 2024 Mar 25]. Available from: https://www.nccn.org/professionals/physician_gls/pdf/nscl.pdf.
8. Ho AT, Gorthi R, Lee R, Chawla M, Patolia S. Solitary lung nodule: CT-guided transthoracic biopsy vs transbronchial biopsy with endobronchial ultrasound and flexible bronchoscope, a meta-analysis of randomized controlled trials. Lung 2023;201:85-93.
9. Yu Lee-Mateus A, Reisenauer J, Garcia-Saucedo JC, Abia-Trujillo D, Buckarma EH, Edell ES, et al. Robotic-assisted bronchoscopy versus CT-guided transthoracic biopsy for diagnosis of pulmonary nodules. Respirology 2023;28:66-73.
10. Kim SH, Mok J, Jo EJ, Kim MH, Lee K, Kim KU, et al. The additive impact of transbronchial cryobiopsy using a 1.1-

mm diameter cryoprobe on conventional biopsy for peripheral lung nodules. Cancer Res Treat 2023;55:506-12.
11. Matsumoto Y, Nakai T, Tanaka M, Imabayashi T, Tsuchida T, Ohe Y. Diagnostic outcomes and safety of cryobiopsy added to conventional sampling methods: an observational study. Chest 2021;160:1890-901.
12. Chung C, Kim Y, Lee JE, Kang DH, Park D. Diagnostic value of transbronchial lung cryobiopsy using an ultrathin cryoprobe and guide sheath for peripheral pulmonary lesions. J Bronchology Interv Pulmonol 2024;31:13-22.
13. Chen A, Chenna P, Loiselle A, Massoni J, Mayse M, Misselhorn D. Radial probe endobronchial ultrasound for peripheral pulmonary lesions: a 5-year institutional experience. Ann Am Thorac Soc 2014;11:578-82.
14. Wang Memoli JS, Nietert PJ, Silvestri GA. Meta-analysis of guided bronchoscopy for the evaluation of the pulmonary nodule. Chest 2012;142:385-93.
15. Sainz Zuniga PV, Vakil E, Molina S, Bassett RL Jr, Ost DE. Sensitivity of radial endobronchial ultrasound-guided bronchoscopy for lung cancer in patients with peripheral pulmonary lesions: an updated meta-analysis. Chest 2020;157:994-1011.
16. Mehta RM, Biraris P, Aurangabadwalla R, Kalpakam H, Bhat R, Bajaj P. Use of an extended working channel in high-risk transbronchial biopsy: an innovative use of an existing modality to minimize bleeding and hypoxia. Innovations (Phila) 2021;16:75-9.
17. Huang CT, Chang LY, Chen CY, Ruan SY, Lin CK, Tsai YJ, et al. Endobronchial ultrasound-guided transbronchial biopsy with or without a guide sheath for peripheral pulmonary malignancy. ERJ Open Res 2021;7:00267-2021.
18. Oki M, Saka H, Imabayashi T, Himeji D, Nishii Y, Nakashima H, et al. Guide sheath versus non-guide sheath method for endobronchial ultrasound-guided biopsy of peripheral pulmonary lesions: a multicentre randomised trial. Eur Respir J 2022;59:2101678.
19. Park S, Yoon HY, Han Y, Wang KS, Park SY, Ryu YJ, et al. Diagnostic yield of additional conventional transbronchial lung biopsy following radial endobronchial ultrasound lung biopsy for peripheral pulmonary lesions. Thorac Cancer 2020;11:1639-46.
20. Kunimasa K, Tachihara M, Tamura D, Tokunaga S, Nakata K, Hazeki N, et al. Diagnostic utility of additional conventional techniques after endobronchial ultrasonography guidance during transbronchial biopsy. Respirology 2016;21:1100-5.
21. Oki M, Saka H. Diagnostic value of ultrathin bronchoscopy in peripheral pulmonary lesions: a narrative review. J Thorac Dis 2020;12:7675-82.
22. Oki M, Saka H, Himeji D, Imabayashi T, Nishii Y, Ando M. Value of adding ultrathin bronchoscopy to thin bronchoscopy for peripheral pulmonary lesions: a multicentre prospective study. Respirology 2023;28:152-8.
23. Pickering EM, Kalchiem-Dekel O, Sachdeva A. Electromagnetic navigation bronchoscopy: a comprehensive review. AME Med J 2018;3:117.
24. Patrucco F, Gavelli F, Daverio M, Antonini C, Boldorini R, Casadio C, et al. Electromagnetic navigation bronchoscopy: where are we now?: five years of a single-center experience. Lung 2018;196:721-7.
25. Seijo LM, de Torres JP, Lozano MD, Bastarrika G, Alcaide AB, Lacunza MM, et al. Diagnostic yield of electromagnetic navigation bronchoscopy is highly dependent on the presence of a bronchus sign on CT imaging: results from a prospective study. Chest 2010;138:1316-21.
26. Yutaka Y, Sato T, Isowa M, Murata Y, Tanaka S, Yamada Y, et al. Electromagnetic navigation bronchoscopy versus virtual bronchoscopy navigation for improving the diagnosis of peripheral lung lesions: analysis of the predictors of successful diagnosis. Surg Today 2022;52:923-30.
27. Folch EE, Pritchett MA, Nead MA, Bowling MR, Murgu SD, Krimsky WS, et al. Electromagnetic navigation bronchoscopy for peripheral pulmonary lesions: one-year results of the prospective, multicenter NAVIGATE study. J Thorac Oncol 2019;14:445-58.
28. Ali MS, Sethi J, Taneja A, Musani A, Maldonado F. Computed tomography bronchus sign and the diagnostic yield of guided bronchoscopy for peripheral pulmonary lesions: a systematic review and meta-analysis. Ann Am Thorac Soc 2018;15:978-87.
29. Folch EE, Bowling MR, Pritchett MA, Murgu SD, Nead MA, Flandes J, et al. NAVIGATE 24-month results: electromagnetic navigation bronchoscopy for pulmonary lesions at 37 centers in Europe and the United States. J Thorac Oncol 2022;17:519-31.
30. Folch EE, Labarca G, Ospina-Delgado D, Kheir F, Majid A, Khandhar SJ, et al. Sensitivity and safety of electromagnetic navigation bronchoscopy for lung cancer diagnosis: systematic review and meta-analysis. Chest 2020;158:1753-69.
31. Chaddha U, Kovacs SP, Manley C, Hogarth DK, Cumbo-Nacheli G, Bhavani SV, et al. Robot-assisted bronchoscopy for pulmonary lesion diagnosis: results from the initial multicenter experience. BMC Pulm Med 2019;19:243.
32. Kalchiem-Dekel O, Connolly JG, Lin IH, Husta BC, Adusumilli PS, Beattie JA, et al. Shape-sensing robotic-assisted bronchoscopy in the diagnosis of pulmonary parenchymal lesions. Chest 2022;161:572-82.
33. Styrvoky K, Schwalk A, Pham D, Chiu HT, Rudkovskaia A, Madsen K, et al. Shape-sensing robotic-assisted bronchoscopy with concurrent use of radial endobronchial ultrasound and cone beam computed tomography in the evaluation of pulmonary lesions. Lung 2022;200:755-61.

34. ClinicalTrials.gov. Clinical utility for ion endoluminal system (ClinicalTrials.gov Identifier: NCT03893539) [Internet]. Bethesda: NIH; 2022 [cited 2024 Mar 25]. Available from: https://classic.clinicaltrials.gov/ct2/show/NCT03893539.
35. Ost D, Pritchett M, Reisenauer J, Simoff M, Diaz-Mendoza J, Fernandez-Bussy S, et al. Prospective multicenter analysis of shape-sensing robotic-assisted bronchoscopy for the biopsy of pulmonary nodules: results from the PRECIsE study. Chest 2021;160:A2531-3.
36. Wikipedia. Joule-Thomson effect [Internet]. San Francisco: Wikimedia; 2024 [cited 2024 Mar 25]. Available from: https://en.wikipedia.org/wiki/Joule%E2%80%93Thomson_effect.
37. Korevaar DA, Colella S, Fally M, Camuset J, Colby TV, Hagmeyer L, et al. European Respiratory Society guidelines on transbronchial lung cryobiopsy in the diagnosis of interstitial lung diseases. Eur Respir J 2022;60:2200425.
38. Wang S, Feng Y, Zhang Y, Tian Y, Gu S, Wu X, et al. Transbronchial lung biopsy versus transbronchial lung cryobiopsy in critically ill patients with undiagnosed acute hypoxemic respiratory failure: a comparative study. BMC Pulm Med 2022;22:177.
39. Oberg CL, Lau RP, Folch EE, He T, Ronaghi R, Susanto I, et al. Novel robotic-assisted cryobiopsy for peripheral pulmonary lesions. Lung 2022;200:737-45.
40. Benn BS, Gmehlin CG, Kurman JS, Doan J. Does transbronchial lung cryobiopsy improve diagnostic yield of digital tomosynthesis-assisted electromagnetic navigation guided bronchoscopic biopsy of pulmonary nodules?: a pilot study. Respir Med 2022;202:106966.
41. Herath S. Using cryobiopsy with radial EBUS in high-bleeding-risk, peripheral pulmonary lesions (PPL): description of cases and technique. Respirol Case Rep 2023;11:e01125.
42. Nakai T, Watanabe T, Kaimi Y, Ogawa K, Matsumoto Y, Sawa K, et al. Safety profile and risk factors for bleeding in transbronchial cryobiopsy using a two-scope technique for peripheral pulmonary lesions. BMC Pulm Med 2022;22:20.
43. Herth FJ, Ernst A, Eberhardt R, Vilmann P, Dienemann H, Krasnik M. Endobronchial ultrasound-guided transbronchial needle aspiration of lymph nodes in the radiologically normal mediastinum. Eur Respir J 2006;28:910-4.
44. Liu YL, Liu XR, Li H, Chen FJ, Liao H, Xie CM. Efficiency of EBUS-TBNA for diagnosing benign and malignant lymphadenopathy. J Acute Dis 2018;7:197-201.
45. Fan Y, Zhang AM, Wu XL, Huang ZS, Kontogianni K, Sun K, et al. Transbronchial needle aspiration combined with cryobiopsy in the diagnosis of mediastinal diseases: a multicentre, open-label, randomised trial. Lancet Respir Med 2023;11:256-64.
46. Zhang J, Guo JR, Huang ZS, Fu WL, Wu XL, Wu N, et al. Transbronchial mediastinal cryobiopsy in the diagnosis of mediastinal lesions: a randomised trial. Eur Respir J 2021;58:2100055.
47. Agrawal A, Ghori U, Chaddha U, Murgu S. Combined EBUS-IFB and EBUS-TBNA vs EBUS-TBNA alone for intrathoracic adenopathy: a meta-analysis. Ann Thorac Surg 2022;114:340-8.
48. Dooms C, Vander Borght S, Yserbyt J, Testelmans D, Wauters E, Nackaerts K, et al. A randomized clinical trial of Flex 19G needles versus 22G needles for endobronchial ultrasonography in suspected lung cancer. Respiration 2018;96:275-82.
49. Kinoshita T, Ujiie H, Schwock J, Fujino K, McDonald C, Lee CY, et al. Clinical evaluation of the utility of a flexible 19-gauge EBUS-TBNA needle. J Thorac Dis 2018;10:2388-96.